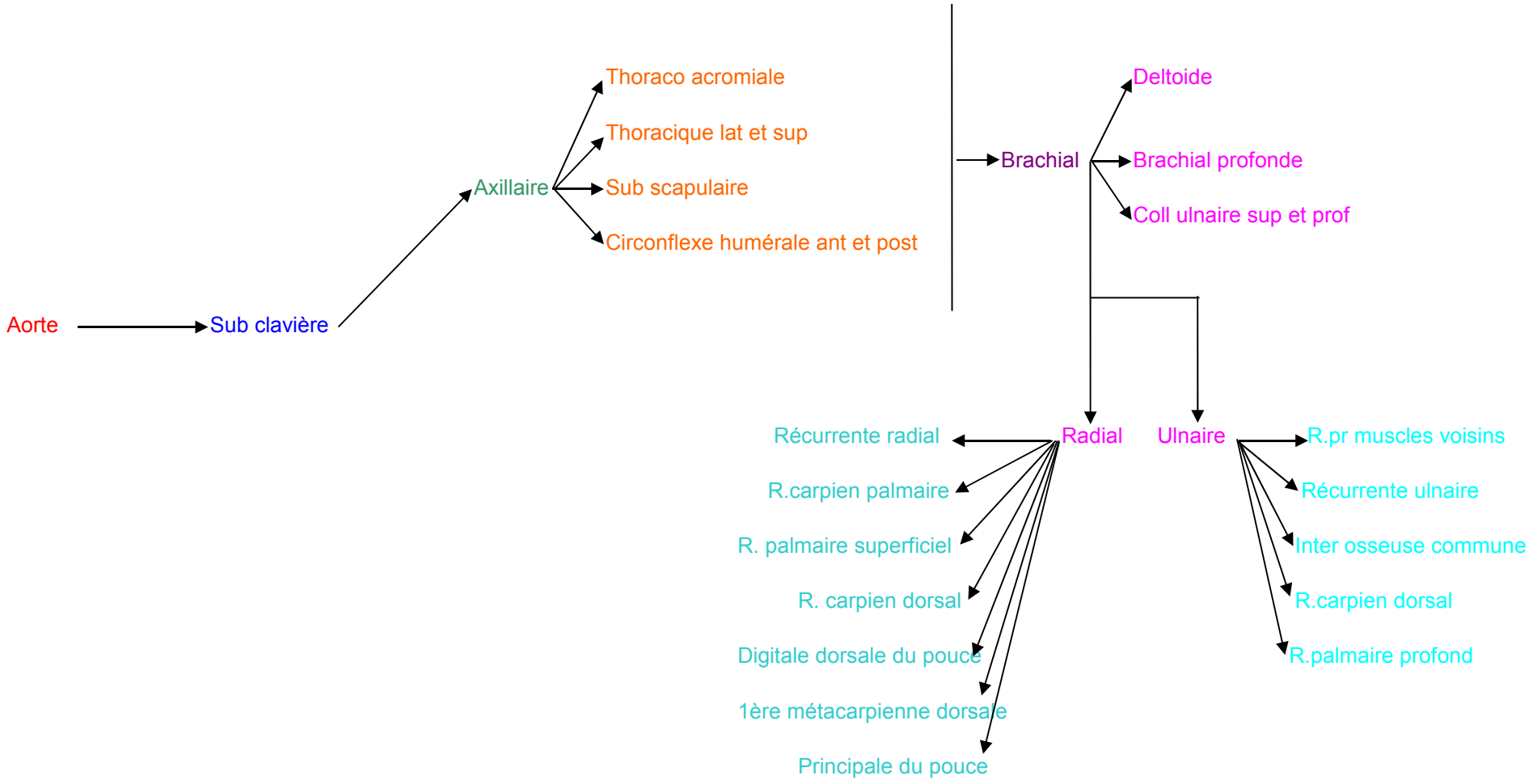LES ARTERES DU MEMBRE SUPERIEUR